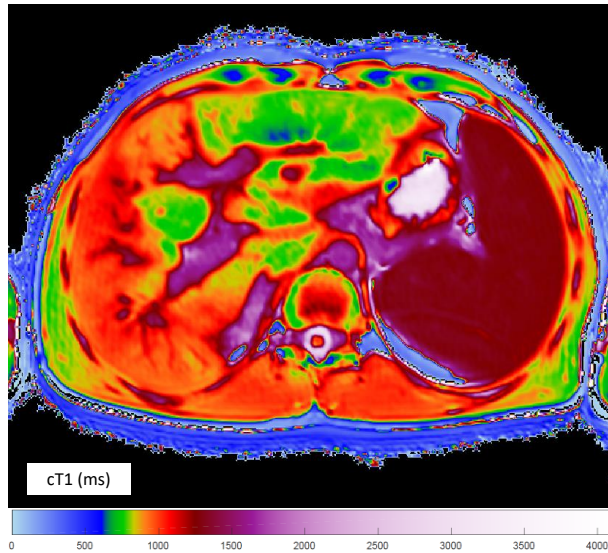


# Case Study: PSC/AIH patient on prednisolone and azathioprine

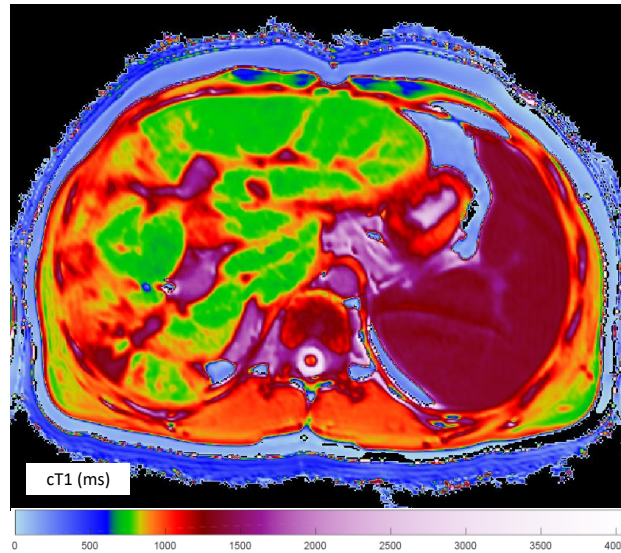
## LiverMultiScan allows the clinician to see heterogeneous liver tissue

22 year old male, with PSC and AIH overlap syndrome; response to treatment.



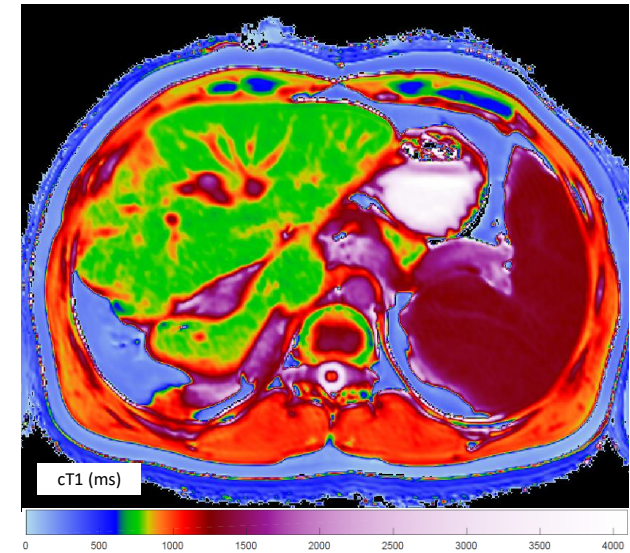
Pre-treatment: February 2012

cT1: 1008ms  
Reference interval: 633ms – 794ms



Post-treatment: October 2012

cT1: 919ms  
Reference interval: 633ms – 794ms



Post-treatment: October 2013

cT1: 826ms  
Reference interval: 633ms – 794ms